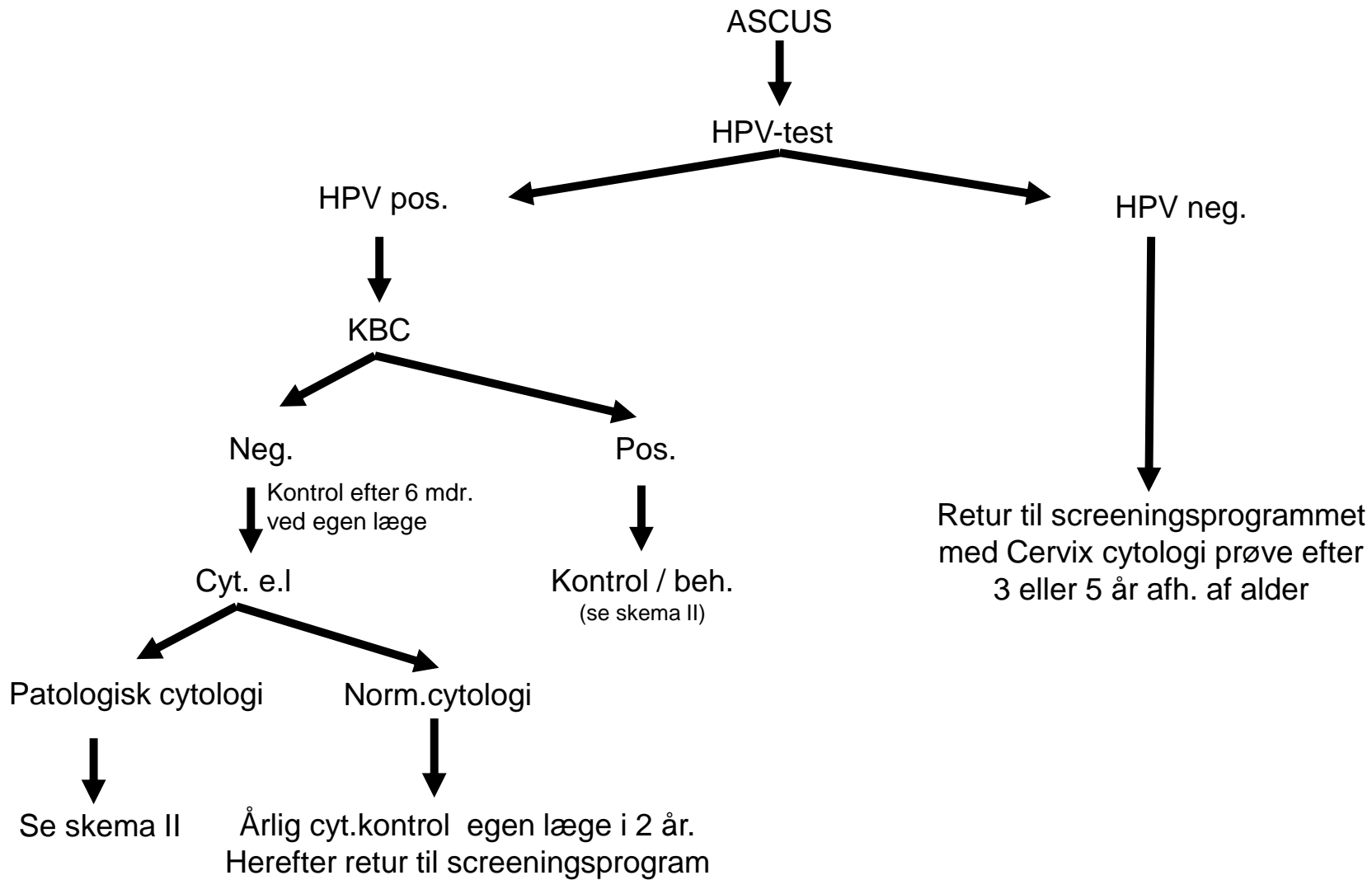
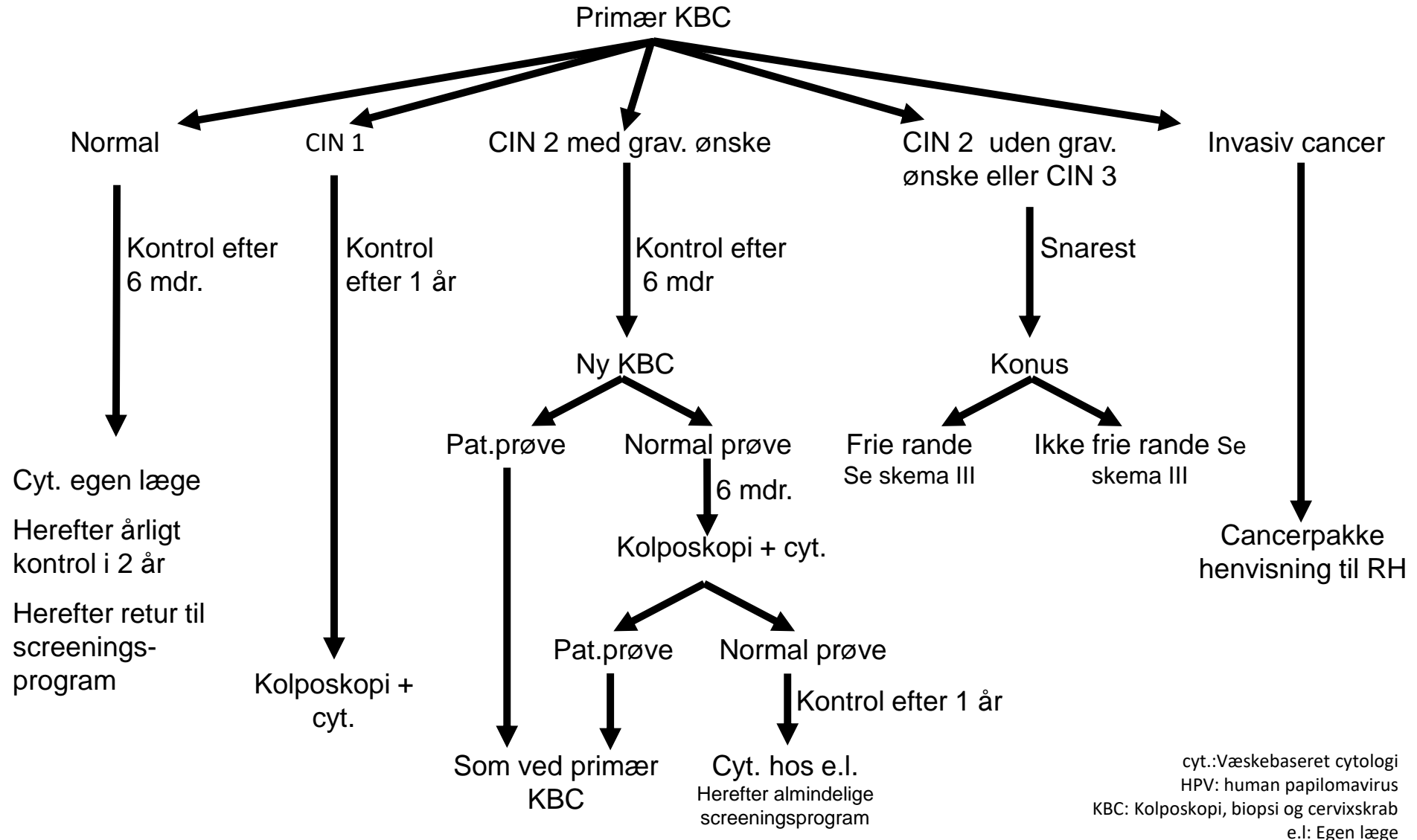


Skema I; Udredning af cytologisk diagnose ASCUS hos kvinder ≥ 30 år



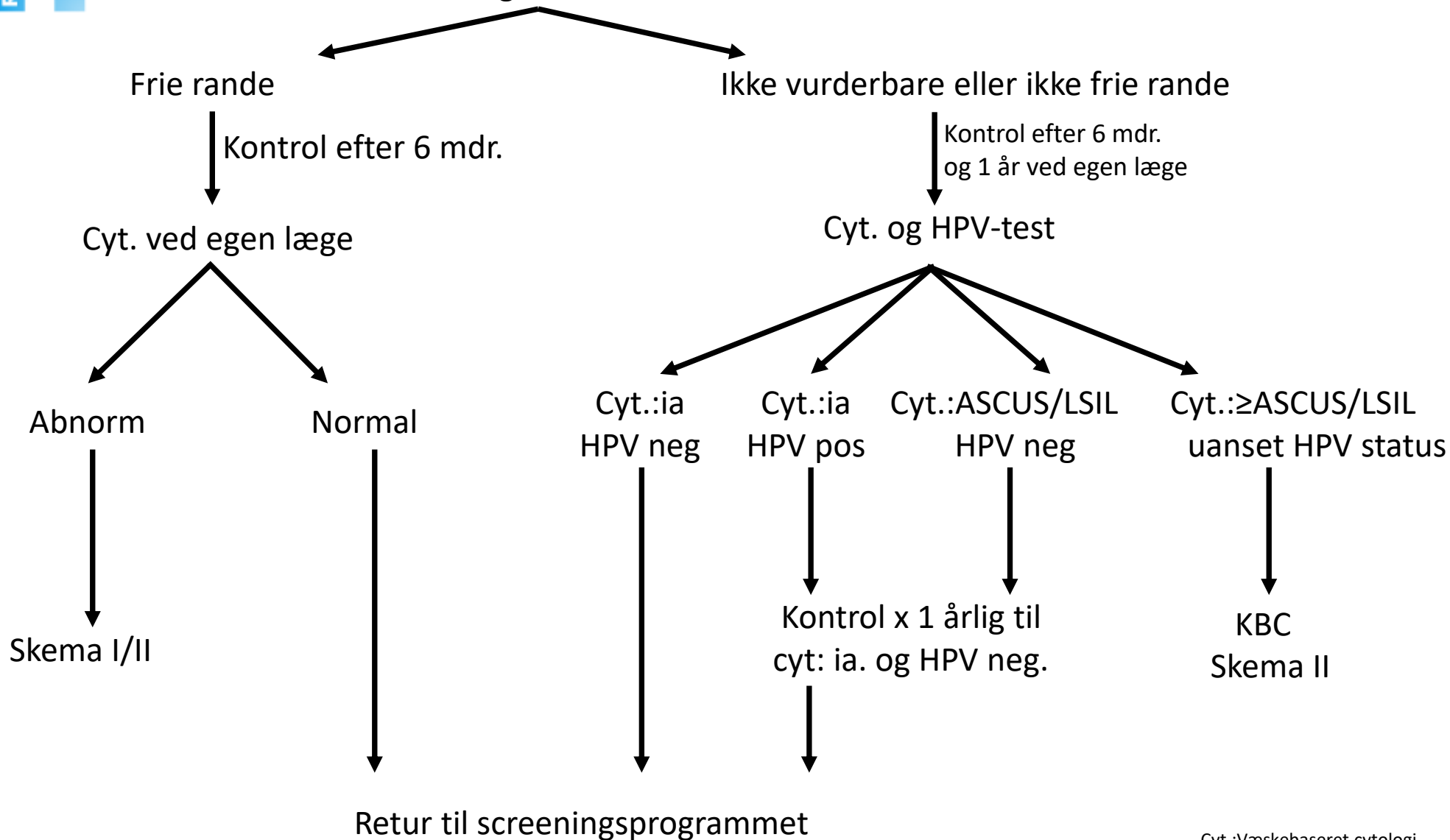
Skema II; Udredning af cervixdysplasi (>70 år se skema IV)

LSIL x 2, HSIL, ASCH, AGC, AIS, Maligne celler,
 ASCUS x 2 hos kvinder < 30 år,
 ASCUS x 1 hos kvinder ≥ 30 år se skema I



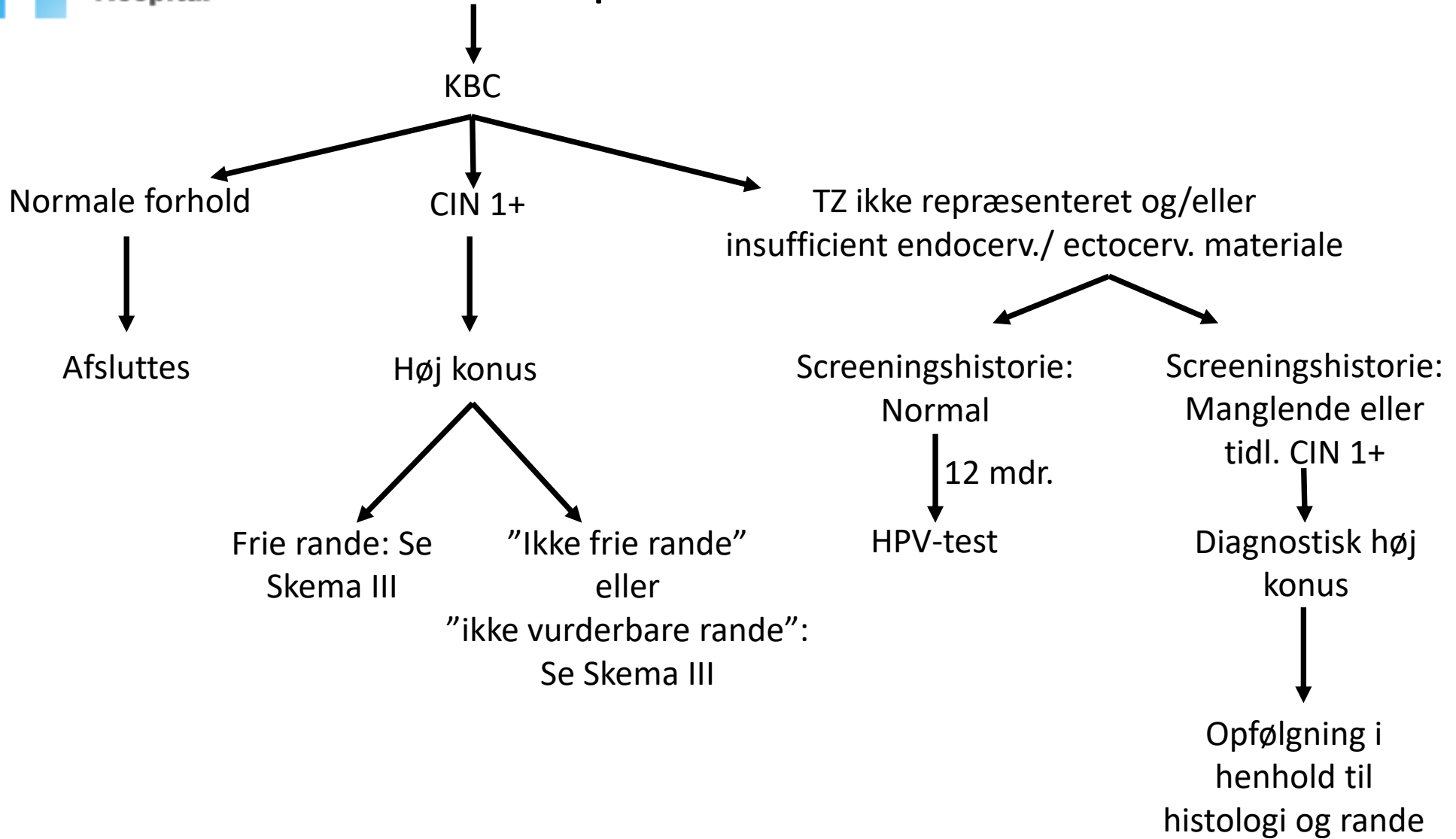
Skema III; Kontrol efter konus

Histologi af konus



Cyt.:Væskebaseret cytologi
 HPV: human papilomavirus
 KBC: Kolposkopi, biopsi og cervixskrab
 e.l.: Egen læge

Skema IV. HR-HPV positiv test blandt kvinder >70 år



HR-HPV pos= High risk human papiloma virus positive
KBC = Kolposkopi , biopsi og cervical abrasio
CIN = cervical intrephitelia neoplasi = dysplasi
TZ = Transformations zonen