

EUROBS 01572

Laparoscopic management of tubal ectopic pregnancy

C. Chapron, J.L. Pouly, A. Wattiez, G. Mage, M. Canis, J. Bouquet, H. Manhes and
M.A. Bruhat

*Polyclinique Gynécologie-Obstétrique, Médecine de la Reproduction, C.H.U. de Clermont-Ferrand, Université de Clermont-Ferrand 1,
13, Bld Charles de Gaulle, 63000 Clermont-Ferrand, Cedex, France*

Summary

As with laparotomy, laparoscopic treatment of ectopic pregnancy (EP) can be either conservative or radical. After conservative laparoscopic treatment by salpingotomy the risk of failure (between 4 and 6%) is comparable with that observed after similar treatment by laparotomy. The fertility results after laparoscopic treatment of EP are comparable if not better than those observed after similar treatment by laparotomy. These two reasons, together with the considerable advantages of endoscopy over laparotomy, mean that today laparoscopic treatment is without question the best surgical treatment for EP. The prognosis for post-EP fertility is unrelated to the characteristics of the EP (size, rupture, location). The post-EP fertility depends mainly on the patient's previous history. We have established the Therapeutic Scoring System for EP by assessing the different factors affecting future fertility and multivariable analysis. This score allowed us to choose the most suitable treatment to preserve fertility and reduce the risk of recurrence between conservative laparoscopic treatment, laparoscopic salpingectomy with or without contralateral tubal sterilization.

ectopic pregnancy; fertility; laparoscopy

Introduction

In 1977, Bruhat and Manhes [1] were the first to describe a method for conservative laparoscopic treatment of ectopic pregnancy (EP). Since then, considerable progress has been made for EP, in two main directions. On the one hand the use of radioimmunological testing of beta hCG levels and endovaginal ultrasonography mean that diagnosis can be made much earlier and far more reliably. On the other hand laparoscopic surgery has proved its worth as the best surgical treatment of EP, with very few, rare exceptions. Comparison of results in terms of failure and subsequent fertili-

ty will, in future, enable the indications for medical treatment of EP to be clarified.

Laparoscopic treatment of EP

As with laparotomy, laparoscopic treatment of EP can be either conservative or radical.

Conservative treatment

For conservative treatment our team always uses the 'Triton', instrument invented by H. Manhes [2]. It is a multi-function device which enables all the phases in laparoscopic conservative treatment of EP to be carried out without chang-

ing instruments. The retractable monopolar electrode is used first for the salpingotomy, then the Triton is introduced into the tube and the trophoblast aspirated. Saline is injected under high pressure to help detach the EP and to carry out the careful lavage of the peritoneum which is the final phase in the operation [3,4].

The main problem with this type of treatment is that there is a 6% risk of failure on average [5,13] (Table I). This failure rate is comparable to that observed with the same type of treatment via laparotomy [14].

The technique must be very rigorously applied to guard against failure. Some of the rules are absolutely essential:

- The salpingotomy must be made in the inner third of the hematosalpinx which is the site of implantation of the trophoblast.
- The salpingotomy must be performed at the antimesenterial border of the tube. When the EP is very large or if there is a lot of oedema it can be very difficult to distinguish this side.
- Conservative treatment by aspiration through the fimbria should be abandoned due to a tripled risk of failure [4,12]. The only exceptions are for the very rare cases where the EP

is located strictly in the fimbria and is already aborting into the abdomen. Whenever there is a hematosalpinx salpingotomy must be carried out without exception.

- The peritoneal lavage at the end of the operation must be carried out systematically and very carefully, because peritoneal trophoblastic implants have been reported after conservative laparoscopic treatment of tubal EP [15,17].

After conservative laparoscopic treatment, failures are diagnosed by monitoring the drop in beta hCG levels [18] (Fig. 1). Monitoring must be continued until negativation. If, 48 h after the operation, the beta hCG level is still over 35% of the pre-operative level, the treatment must be considered to have failed. If this diagnosis is based purely on the biology results, intramuscular injection of methotrexate should be used. However, any clinical symptoms combined with the abnormal downward curve of the beta hCGs mean that a second laparoscopy should be carried out [18].

Radical treatment

This treatment, proposed by Dubuisson [19] consists of a retrograde salpingectomy. The isthmus tube is coagulated at one centimeter from the uterine horn and transected. Thereafter the mesosalpinx is alternatively coagulated and transected remaining as close as possible to the tube. The tube is then removed via one of the suprapubic incisions. If the EP is very voluminous it may be necessary to incise the tube and aspirate the EP before extracting the tube. In exceptional cases the EP may be extracted via culdotomy. The various manoeuvres can result in trophoblast tissue dropping into the pouch of Douglas, so, as with conservative treatment, the operation must terminate with careful peritoneal lavage.

Strategy for surgical treatment of EP

Do any indications remain for laparotomy?

The risk of failure and the fertility results after conservative laparoscopic treatment are comparable to those with equivalent techniques via laparotomy [3,20]. In our opinion therefore the only

TABLE I

Failure of conservative laparoscopic treatment of EP by salpingotomy

Authors	Year	No. of EPs	Failures ^a	
			n	%
Cartwright [5]	1986	20	1	5
Pouly [6]	1986	321	15	4.8
De Cherney [7]	1987	79	2	2.5
Reich [8]	1988	65	4	6
Vermesh [9]	1989	30	1	3.3
Donnez [10]	1990	300	17	5.7
Seifer [11]	1990	81	11	13.6
Chapron [12]	1991	45	3	6.7
Lundorff [13]	1991	52	5	9.6
Total		993	59	5.94

^aFailures requiring surgical or medical treatment

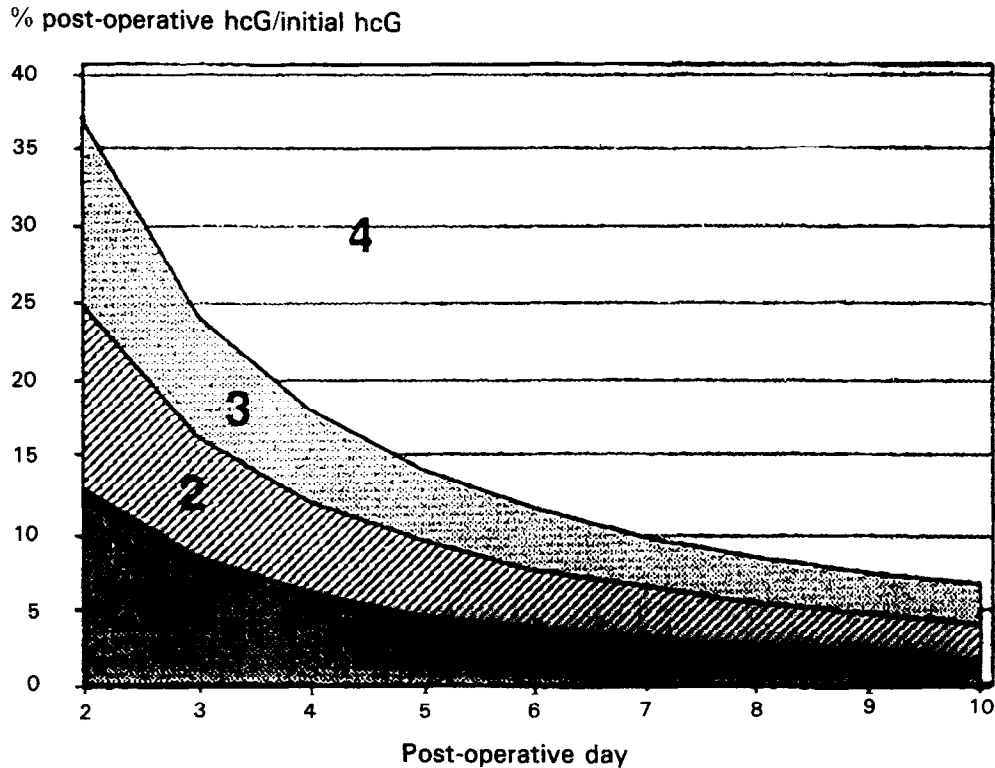


Fig. 1. Corrected curves of hCG levels given as relative values, according to the post-operative days in successful cases (curves per mean values, mean \pm S.D., mean \pm 2 S.D.) and in cases of failure (black squares) and diagram indicating the post-operative procedure: Zona 1: monitoring necessary; Zona 2: likely successful treatment but continuous monitoring until negatvation if high hCG initial level ($>$ 200 ng/ml); Zona 3: strict monitoring until negatvation of hCG level; Zona 4: very likely failure. From: Pouly JL, Chapron C, Mage G et al., J Gynecol Surg 1991;7:211-217.

indications for laparotomy are those where laparoscopic treatment is counter-indicated. Two of these are mandatory. They are when laparoscopic anesthesia is counter-indicated and a state of hemodynamic shock. In the special case of interstitial EP, although laparoscopic treatment has been reported [21,22], we prefer laparotomy or medical treatment by injection of methotrexate, either systemically or guided by ultrasound [23]. The other counter-indications (size of the EP, volume of the hemoperitoneum, presence of adhesions, encysted hematocele, obesity) are only relative and depend solely on the surgeon's degree of experience and skill in laparoscopy.

Should laparoscopic treatment be conservative or radical?

The overall fertility results after laparoscopic treatment are clearly in favour of conservative treatment. It offers a better chance of intrauterine pregnancy (IUP) than radical treatment without any corresponding increase in the risk of recurrence (Table II).

If these elements speak in favour of conservative treatment, the indications for salpingotomy and salpingectomy, respectively, must be confirmed by analysis of these results in terms of factors affecting future fertility. Our work [20] has demonstrated that the fertility prognosis is unrelated to

TABLE II

Fertility after laparoscopic treatment of ectopic pregnancy

Authors	Year	Type of treatment	No.	IUP		EP	
				n	%	n	%
De Cherney [7]	1987	C	69	36	52	7	16
Donnez [10]	1990	C	138	70	51	14	10
Pouly [20]	1990	C	223	149	67	27	12
Total			430	255	59	48	11
Reich [8]	1988	C + R	38	19	50	11	29
Mecke [24]	1989	C + R	74	42	57	10	14
Total			112	61	54	21	18
Dubuisson [25]	1990	R	125	30	24	16	13

C, conservative laparoscopic treatment; R, radical laparoscopic treatment.

the characteristics of the EP, but depends solely on the patient's previous history (Table III).

For us the fact that the characteristics of the EP have no effect on the fertility prognosis has several practical consequences:

- The size of the EP is not a factor to be taken into consideration when choosing how to carry out laparoscopic treatment.

- The rupture of the tube is not in itself a systematic indication for salpingectomy. The likelihood of IUP or recurrence after conservative treatment is comparable whether the tube is ruptured or not.
- The location of the tubal EP has no effect on future fertility. This means that conservative laparoscopic surgery can be proposed for all types of EP including those of the isthmus [26].

TABLE III

Fertility prognosis factors after laparoscopic treatment of EP

Factors without influence on the prognosis	Factors which influence the prognosis
— Size of EP	— Homolateral adhesions
— Amount of hemo-peritoneum	— State of contralateral tube
— Site of EP	— Antecedents +++
— Tubal rupture	* EP
	* Salpingitis
	* Solitary tube
	* Tubal microsurgery
	* Laparoscopic adhesiolysis

From: Pouly JL, Chapron C, Manhes H et al. *Fertil Steril* 1991;56:453-460.

The patient's antecedents (EP, salpingitis, solitary tube, tubal surgery, sterility) are the main factors affecting the prognosis for fertility after EP. This part played by past history in the prognosis explains the very good fertility results for patients presenting an EP with an IUD, because they had a significantly lower incidence of this type of factor when compared with patients who did not have an IUD when the diagnosis of EP was made [27].

The patient's antecedents affect fertility in various ways [20]:

- They significantly affect overall fertility rates by reducing the chance of IUP and increasing the risk of recurrence.

- They significantly reduce the cumulative IUP pregnancy rates.
- They delay the onset of IUP.
- They act in favour of homolateral recurrence [28]. For patients presenting a recurrence after a first EP, this is homolateral in 66% of cases, but this drops to 45% for patients without tube sterility factors.
- Finally, not all the factors have the same adverse effect on fertility. Multivariable analysis has enabled us to evaluate the relative responsibility of each of the factors that was found to adversely affect the infertility prognosis. A proportional coefficient for each then enables us to propose a Therapeutic Scoring System for EP [35] (Table IV). Analysis of the fertility results in the light of this score clearly shows that the IUP rate varies inversely with the score, whereas the rate for recurrences varies directly [20].

Taken together these observations enable us to propose the following attitudes to surgical treatment of EP, depending on the EP Therapeutic Score, and excluding the rare cases where endoscopic treatment is counter-indicated.

TABLE IV

Therapeutic scoring system for ectopic pregnancy

Factors significantly affecting fertility after EP	Statistical weighting	Coefficient
Antecedent: one EP	0.434	2
For each further EP	0.261	1
Antecedent: laparoscopic adhesiolysis ^a	0.258	1
Antecedent: tubal microsurgery	0.351	2
Solitary tube	0.472	2
Antecedent: salpingitis	0.242	1
Homolateral adhesions	0.207	1
Contralateral adhesions ^b	0.198	1

^aCount only one occasion.

^bIf the contralateral tube is missing or obstructed, count as solitary tube.

Score 1 to 4: Conservative laparoscopic treatment

This choice is motivated by three factors:

- The likelihood of IUP is greater after conservative treatment.
- Radical treatment does not eliminate the risk of recurrence.
- For this type of patient, whose past history is relatively clear, recurrence affects both tubes with the same frequency.

For two reasons we recommend, as conservative laparoscopic treatment, the salpingotomy without suture [29]. Aspiration through the fimbria should be abandoned because the risk of failure is too high and the results observed after laparoscopic salpingotomy followed by suture [24] show no significant difference to those we obtained [20]. This is confirmed by the results of the random prospective study carried out via laparotomy by Tulandi and Guralnick [30] in which they demonstrate that whereas the cumulative IUP rate is comparable at 2 years whether the salpingotomy has been sutured or not, pregnancy occurs far quicker when the tube is not sutured.

Score 5: Radical laparoscopic treatment

These patients stand an equal chance of IUP or recurrence after conservative laparoscopic treatment [20]. Their tubal antecedents are considerable so salpingectomy will avoid the 80% risk of homolateral recurrence, thus giving them a higher chance of IUP than recurrence.

Score 6 and over: Radical laparoscopic treatment and contralateral sterilization

The chance these patients have for IUP is not only very low but considerably below that of recurrence [20]. IVF will offer them far more likelihood of becoming pregnant with a risk of EP of about 4–5% [31].

Conclusion

These results demonstrate that surgical treatment today should be via laparoscopy, except for a few special cases, and that conservative treat-

ment by salpingotomy without suture is the best to safeguard for future fertility.

This type of treatment is not indicated in absolutely every case, however. The EP Therapeutic Scoring System based essentially on the patient's previous history means that before surgery actually begins the patient can be offered the treatment which will best preserve her future fertility.

The alternative treatment for EP is medical. If the risk of failure and fertility prognosis after this prove in the future to be comparable with those obtained after endoscopic treatment, the problem will then be to know how to decide which patients can be allowed medical treatment and which remain within the indications for laparoscopic surgery.

References

- 1 Bruhat MA, Manhes H, Choukroun J, Suzanne F. Essai de traitement percoelioscopique de la grossesse extra-utérine. A propos de 26 observations. *Rev Fr Gynecol Obstet* 1977;72:667-669.
- 2 Manhes H, Mage G, Pouly JL, Ropert JF, Bruhat MA. Traitement coelioscopique de la grossesse tubaire: ameliorations techniques. *Presse Med* 1983;12:1431.
- 3 Bruhat MA, Mage G, Pouly JL, Manhes H, Canis M, Wattiez A, in Medsi (Ed.), *Operative Laparoscopy*. McGraw-Hill, Inc. New York, 1992, 226 pp.
- 4 Bruhat MA, Manhes H, Mage G, Pouly JL. Treatment of ectopic pregnancy by means of laparoscopy. *Fertil Steril* 1980;33:411-414.
- 5 Cartwright PS, Hertbert III CM, Maxon W. Operative laparoscopy for the management of tubal pregnancy. *J Reprod Med* 1986;31:589-591.
- 6 Pouly JL, Manhes H, Mage G, Canis M, Bruhat MA. Conservative laparoscopic treatment of 321 ectopic pregnancies. *Fertil Steril* 1986;46:1093-1097.
- 7 DeCherney AH, Diamond MP. Laparoscopic salpingostomy for ectopic pregnancy. *Obstet Gynecol* 1987;70:948-950.
- 8 Reich H, Johns DA, DeCaprio J, McGlynn F, Reich E. Laparoscopic treatment of 109 consecutive ectopic pregnancies. *J Reprod Med* 1988;33:885-890.
- 9 Vermesh M, Silva PD, Rosen GF, Stein AL, Fossum GT, Sauer MV. Management of unruptured ectopic gestation by linear salpingostomy: A prospective, randomized clinical trial of laparoscopy versus laparotomy. *Obstet Gynecol* 1989;73:400-404.
- 10 Donnez J, Nisolle M. Laparoscopic treatment of ampullary tubal pregnancy. *J Gynecol Surg* 1989;5:157-162.
- 11 Seifer DB, Gutmann JN, Doyle MB, Jones EE, Diamond MP, DeCherney AH. Persistent ectopic pregnancy following laparoscopic linear salpingostomy. *Obstet Gynecol* 1990;76:1121-1125.
- 12 Chapron C, Querleu D, Crepin G. Laparoscopic treatment of ectopic pregnancies. A one hundred cases study. *Eur J Obstet Gynecol Reprod Biol* 1991;41:187-190.
- 13 Lundorff P, Hahlin M, Sjöblom P, Lindblom B. Persistent trophoblast after conservative treatment of tubal pregnancy: Prediction and detection. *Obstet Gynecol* 1991;77:129-133.
- 14 Di Marchi JM, Losasa TS, Lobara TY. Persistent ectopic pregnancy. *Obstet Gynecol* 1987;70:55-558.
- 15 Cartwright PS. Peritoneal trophoblastic implants after surgical management of tubal pregnancy. *J Reprod Med* 1991;36:523-524.
- 16 Reich H, DeCaprio J, McGlynn F, Wilkie WL, Longo S. Peritoneal trophoblastic tissue implants after laparoscopic treatment of tubal ectopic pregnancy. *Fertil Steril* 1989;52:337-339.
- 17 Thatcher SS, Graiger DA, True LD, DeCherney AH. Pelvic trophoblastic implants after laparoscopic removal of a tubal pregnancy. *Obstet Gynecol* 1989;74:514-514.
- 18 Pouly JL, Chapron C, Mage G, Manhes H, Wattiez A, Canis M, Gaillard G, Bruhat MA. The drop in the level of hCG after conservative laparoscopic treatment of ectopic pregnancy. *J Gynecol Surg* 1991;7:211-217.
- 19 Dubuisson JB, Aubriot FX, Cardone V. Laproscopic salpingectomy for tubal pregnancy. *Fertil Steril* 1987;47:225-228.
- 20 Pouly JL, Chapron C, Manhes H, Canis M, Wattiez A, Bruhat MA. Multifactorial analysis of fertility after conservative laparoscopic treatment of ectopic pregnancy in a series of 223 patients. *Fertil Steril* 1991;56:453-460.
- 21 Hill GA, Segars Jr JR, Herbert III CM. Laparoscopic management of interstitial pregnancy. *J Gynecol Surg* 1989;5:209-212.
- 22 Reich H, McGlynn F, Budin R, Tsoutsoplides G, DeCaprio J. Laparoscopic treatment of ruptured interstitial pregnancy. *J Gynecol Surg* 1990;6:135-138.
- 23 Fernandez H, DeZiegler D, Bourget P, Feltain P, Frydman R. The place of methotrexate in the management of interstitial pregnancy. *Hum Reprod* 1991;6:302-306.
- 24 Mecke H, Semm K, Lehmann-Willenbrock E. Results of operative pelviscopy in 202 cases of ectopic pregnancy. *Int J Fertil* 1989;34:93-100.
- 25 Dubuisson JB, Aubriot FX, Foulot H, Bruel D, Bouquet de Joliniere J, Mandelbrot L. Reproductive outcome after laparoscopic salpingectomy for tubal pregnancy. *Fertil Steril* 1990;53:1004-1007.
- 26 Chapron C, Pouly JL, Wattiez A, Mage G, Canis M, Manhes H, Bruhat MA. Results of conservative laparoscopic treatment of isthmic ectopic pregnancies; a 26 cases study. *Hum Reprod* 1992;7:422-424.
- 27 Pouly JL, Chapron C, Canis M, Mage G, Wattiez A, Manhes H, Bruhat MA. Subsequent fertility for patients presenting with an ectopic pregnancy and having an intra-uterine device in situ. *Hum Reprod* 1991;6:999-1001.

- 28 Chapron C, Pouly JL, Mage G, Canis M, Wattiez A, Bassil S, Manhes H, Bruhat MA. Récidives après traitement coelioscopique conservateur d'une première grossesse extra-utérine. *J Gynecol Obstet Biol Reprod* 1992;21:59-64.
- 29 Chapron C, Pouly JL, Manhes H, Mage G, Canis M, Wattiez A, Bruhat MA. Treatment of tubal pregnancy. *Fertil Steril (letter)* 1991;56:374-375.
- 30 Tulandi T, Guralnick M. Treatment of tubal ectopic pregnancy by salpingotomy with or without tubal suturing and salpingectomy. *Fertil Steril* 1991;55:53-55.
- 31 MRI and AFS: In vitro fertilization-embryo transfer in the United States: 1988 results from the IVF-ET Registry. *Fertil Steril* 1990;53:13-20.