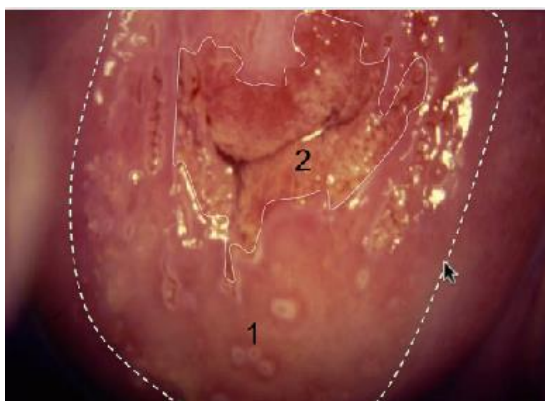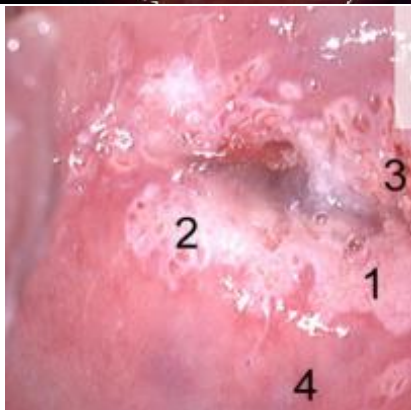


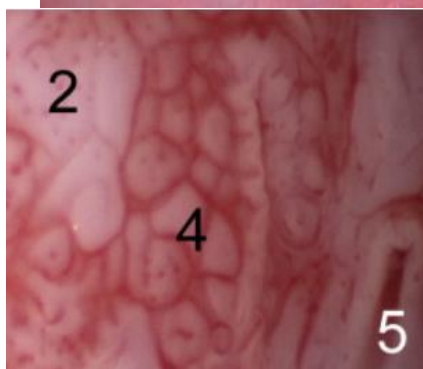Normal Cervix

- Stiplet linie oprindeling SQJ
- Tynd stiplet linie Ny SQJ
- 1. TZ (m lukkede krypter)
- 2. normalt cylinder epithel.



Lette forandringer

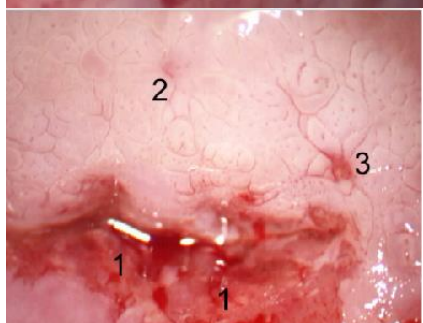
1. Fin mosaic
2. Lette acetowhite forandringer
3. Cylinderepithel
4. TZ (Metaplastisk epithel)



Svære forandringer

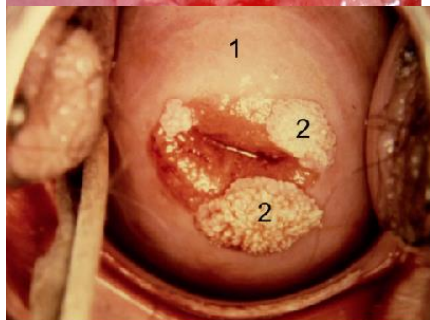
2. grov punktuation
4. grov mosaic
5. krypt "med krave"

Formentlig CIN3 forandringer.



Malignitets suspect

1. Blødende epithel, skrøbelige kar
2. Grov mosaic og punktuation
3. Abnorme kar



Kondylomer

1. Lette acetowhite forandringer
2. Cervicale kondylomer