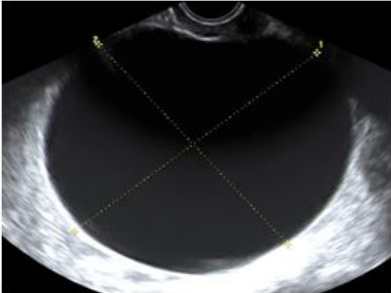
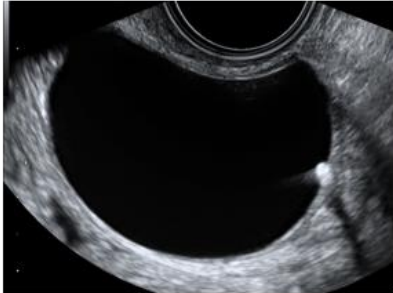


IOTA modellen (2008)

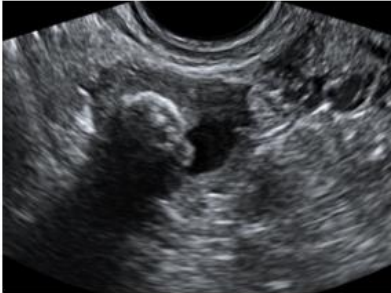B1 Unilocular



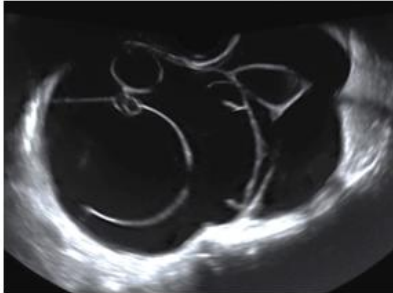
B2 Presence of solid components with largest diameter < 7 mm



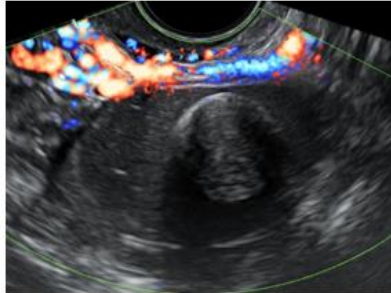
B3 Presence of acoustic shadows



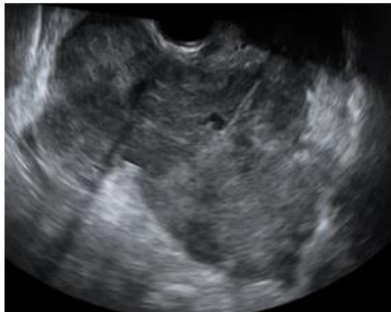
B4 Smooth multilocular tumor with largest diameter < 100 mm



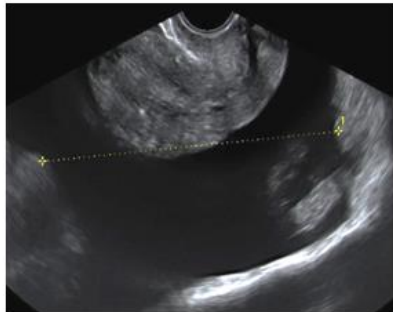
B5 No blood flow (color score 1)



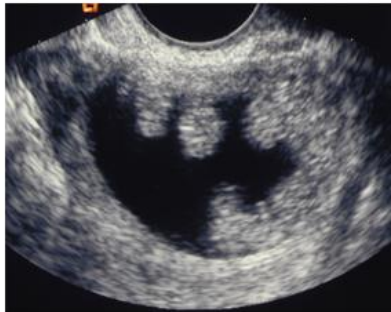M1 Irregular solid tumor



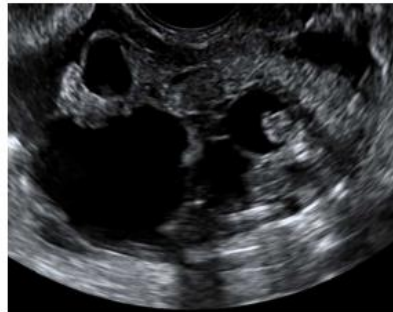
M2 Presence of ascites



M3 At least 4 papillary structures



M4 Irregular multilocular-solid tumor with largest diameter >= 100 mm



M5 Very strong blood flow (color score 4)

